



Contents lists available at ScienceDirect

Journal of Prosthodontic Research

journal homepage: www.elsevier.com/locate/jpor



Original article

Cross-sectional observational study exploring clinical risk of titanium allergy caused by dental implants

Maki Hosoki, Keisuke Nishigawa, Toyoko Tajima, Mayu Ueda, Yoshizo Matsuka*

Department of Stomatognathic Function and Occlusal Reconstruction, Institute of Biomedical Sciences, Tokushima University Graduate School, Tokushima, Japan

ARTICLE INFO

Article history:

Received 16 November 2016
Received in revised form 1 February 2018
Accepted 6 March 2018
Available online xxx

Keywords:

Metal allergy
Titanium
Dental implants
Patch testing
Epidemiology

ABSTRACT

Purpose: Studies have reported cases of metal allergy caused by titanium-containing materials. We wished to clarify the relationship between titanium allergy and dental implants by describing patients who suffered allergic symptoms after they had received such implants.

Methods: A total of 270 patients who visited a Dental Metal Allergy Clinic at Tokushima University Hospital from April 2010 to March 2014 were the study cohort. Patch testing with 28 types of metal allergens (including four titanium allergens) was undertaken for patients.

Results: A total of 217 patients (80.4 %) exhibited allergy-positive reactions to at least one type of metal allergen. Mercury, palladium, chromium and nickel exhibited a higher prevalence of allergy-positive reactions than other metals. Sixteen patients visited our clinic suffering allergic symptoms after receiving dental implants. Eleven of those patients exhibited allergy-positive reactions for any of the metal allergens, and 4 of these patients had allergy-positive reactions against titanium allergens. The total number of allergy-positive reactions for titanium allergens among all 270 patients was 17 (6.3 %). No patient exhibited a positive reaction only for the titanium allergen.

Conclusions: The prevalence of allergy-positive reactions for titanium allergens was lower than for other metal allergens. We suggest examination of pre-implant patients who have a history of hypersensitivity reactions to metals.

© 2018 Japan Prosthodontic Society. Published by Elsevier Ltd. All rights reserved. This is an open access article under the CC BY-NC-ND license (<http://creativecommons.org/licenses/by-nc-nd/4.0/>).

1. Introduction

Various types of metallic and organic materials have been used for dental treatment. Some of these materials have been reported to have pro-allergenic properties. In 1982, Fleischmann was the first to report that stomatitis and anocutaneous dermatitis are caused by mercury from amalgam fillings [1]. One year later, Blumenthal reported similar symptoms caused by amalgam fillings [2]. After publication of those reports, several studies from different countries detailed cases of allergy caused by mercury, nickel, chromium, palladium and cobalt [3–5]. Allergic symptoms from these materials were not restricted to the mouth: they were also found on the hands, legs and skin [6–9].

Allergy to dental metals (also termed “dental metal allergy” [DMA]) is a component of metal allergy caused by the metal materials used in dental treatment. In 1987, Tokushima University

Hospital (Tokushima, Japan) set up a DMA Clinic. Since then, we have been engaged in the treatment of DMA patients and have reported the results of etiological investigations among such patients [8,9]. The prevalence of DMA has increased gradually compared with that reported by our research team previously.

Since surface of titanium metal was passivated with chemically stable titanium oxide, this material exhibits several properties that enable it to be used as a biomaterial: chemical stability, non-erosion and high biocompatibility. Titanium was considered to be a non-allergenic material [10,11], so many products containing titanium were used in plastic surgery and dental implants. Some early studies reported on allergy cases caused by titanium orthodontic appliances and the titanium frames of spectacles. However, in those reports the actual cause of allergic symptoms was the nickel [12–14] and/or palladium ingredients in titanium alloys [15–17]. Hence, a “genuine” example of titanium allergy was not known until since around the 1990's.

Several scholars have reported cases of suspected titanium allergy [18–24]. Peters et al. described a patient who had repeated implantation and removal of cardiac pacemakers because of pruritus, redness, and swelling of the skin overlying a titanium-

* Corresponding author at: Department of Stomatognathic Function and Occlusal Reconstruction, Institute of Biomedical Sciences, Tokushima University Graduate School, 3-18-15 Kuramoto-cho, Tokushima 770-8504, Japan.

E-mail address: matsuka@tokushima-u.ac.jp (Y. Matsuka).

<https://doi.org/10.1016/j.jpor.2018.03.003>

1883-1958/© 2018 Japan Prosthodontic Society. Published by Elsevier Ltd. This is an open access article under the CC BY-NC-ND license (<http://creativecommons.org/licenses/by-nc-nd/4.0/>).

Table 1
Referral source in this study cohort

Referral source	Numbers
Referred from other dental departments	125
at Tokushima University Hospital	
Referred from other medical departments at Tokushima University Hospital	13
Referrals from other dental clinics	101
Referrals from other hospitals	21
Self-referred	10
Total patients	270

containing pacemaker [18]. Lalor et al. described titanium-sensitive patients who underwent revision procedures for failed total hip replacements [19]. Thomas et al. reported a patient who developed eczema upon titanium-based osteosynthesis [22]. Egusa et al. reported facial eczema in association with a titanium dental implant [23]. Siddiqi et al. wrote a review of the literature suggesting that titanium can induce hypersensitivity in susceptible patients and could have a critical role in implant failure [24].

This is a cross-sectional observational study of titanium dental implants on dental metal allergy based on patients who attended the DMA Clinic in Tokushima University Hospital. We clarified the relationship between titanium allergy and the dental implant by describing patients who suffered allergic symptoms after they had received dental implants. Null hypothesis of this study is that there is no patient who suffers allergy symptoms caused with titanium dental implant.

2. Materials and methods

2.1. Ethical approval of the study protocol

The study protocol was in accordance with the Helsinki Declaration and was approved by the Research Ethics Committee of Tokushima University Hospital (number 1036).

2.2. Participants

All of 270 outpatients (61 males and 209 females) who visited the DMA Clinic within Tokushima University Hospital with a suspected diagnosis of DMA from April 2010 to March 2014 were investigated. The mean age of these patients was 53.9 (range, 7–85) years. A total of 260 patients (96.3 %) were referred by other institutions (Table 1).

2.3. Methods

All patients underwent a general examination and intra-oral examination by dentists with more than 20 years' experience in the DMA Clinic. Afterwards, a patch test with 28 types of metal allergens was undertaken to identify allergenic metallic material. Our clinic uses 17 patch-test metal allergens (Patch Test Reagents; Torii Pharmaceutical Corpo., Tokyo, Japan) and 11 custom-made allergens [25–27]. These allergens include most of the metallic elements that are the main ingredients of alloys used for dental treatment in Japan. These allergens were attached to the skin on the back of patients with an adhesive plaster (Patch Tester Torii; Torii Pharmaceutical Corp.) and removed after 2 days. Skin reactions were classified after 2 days, 3 days and 7 days after initial attachment using criteria set by the International Contact Dermatitis Research Group [26,28,29]. The results of the patch test were stored with the hospital records of patients, including the diagnosis and allergic symptoms [29] (Table 2). Treatment plan for these patients is standing for comprehensive diagnosis of the

Table 2
Diagnostic standard of allergy [29]

–	–	–	Negative	–	–	–	Negative
		±	Re-test			±	Re-test
		+	Positive			+	Positive
		++	Positive			++	Positive
	±	–	Negative		±	–	Negative
		±	Re-test			±	Re-test
		+	Positive			+	Positive
		++	Positive			++	Positive
	+	–	Re-test		+	–	Re-test
		±	Re-test			±	Positive
		+	Positive			+	Positive
		++	Positive			++	Positive
	++	–	Re-test		++	–	Re-test
		±	Re-test			±	Positive
		+	Positive			+	Positive
		++	Positive			++	Positive
±	–	–	Negative	++	–	–	Negative
		±	Re-test			±	Re-test
		+	Positive			+	Re-test
		++	Positive			++	Re-test
	±	–	Negative		±	–	Negative
		±	Re-test			±	Re-test
		+	Positive			+	Positive
		++	Positive			++	Positive
	+	–	Re-test		+	–	Re-test
		±	Positive			±	Positive
		+	Positive			+	Positive
		++	Positive			++	Positive
	++	–	Re-test		++	–	Re-test
		±	Positive			±	Positive
		+	Positive			+	Positive
		++	Positive			++	Positive
D2	D3	D7	Comprehensive judgment	D2	D3	D7	Comprehensive judgment

D2: 2 days after pasting, D3: 3 days after pasting, D7: 7 days after pasting.

allergy symptoms. Outcome of patch test, ionization of restoration, intraoral examination of the dental metal materials that reacted with patch test, physical findings of general allergy are involved in those diagnosis.

Histories of having dental implants and of contact dermatitis for jewelry were used as categorical variables to divide patients into two groups. The chi-square test was used to observe a relationship between implantation and allergy-positive metal reactions in these patients. Statistical analyses were carried out using SPSS v14.0J (SPSS Japan, Tokyo, Japan).

3. Results

3.1. Prevalence of allergy-positive reactions to metal allergens

A total of 217 patients (80.4 %) exhibited an allergy-positive reaction to at least one type of metal allergen. Typical allergic symptoms and diagnoses of these 270 patients are shown in Table 3. Lichen planus, pustulosis palmaris et plantaris, stomatitis/cheilitis/gingivitis, and glossitis/sensations in the lingual nerve were observed frequently. These symptoms showed prevalence that was similar to that documented in our previous study. Pustulosis palmaris et plantaris and contact dermatitis have only cutaneous symptoms, and concomitant intraoral symptoms were not observed in most cases. The prevalence of positive reactions for all patch-test allergens is shown in Table 4. In order of frequency, positive reactions were found to mercury, palladium, chromium, nickel, cobalt and tin. Barium, titanium, silver, manganese, antimony and aluminum exhibited the lowest prevalence of positive reactions.

Sixteen patients (7 males, 9 females) had dental implants. The mean age of these patients was 65.1 (57–79) years, and they

Table 3

Typical symptoms or diagnoses in the study cohort

Lichen planus	58	21.4
Pustulosis palmaris et plantaris/dyshidrotic eczema	27	10.5
Stomatitis/cheilitis/gingivitis	20	7.4
Glossitis/sensation in the lingual nerve	18	6.7
Eczema	14	5.2
Contact dermatitis	13	4.8
Rash	11	4.1
Atopic dermatitis	10	3.7
Urticaria	9	3.3
Food allergy	9	3.3
Itching, pain	6	2.2
Redness (hands and feet/face/body)	2	0.7
Redness (oral cavity)	2	0.7
Others	71	26.3
Total	270	100
Typical symptoms or diagnoses	Number	%

visited our DMA Clinic with allergic symptoms after receiving dental implants. Patients with dental implants exhibited a prevalence of allergy-positive reactions of 68.8 % to at least one type of metal allergen. Patients without dental implants exhibited a prevalence of allergy-positive reactions of 81.1 % to at least one type of metal allergen. Patients with dental implants exhibited a lower prevalence of positive reactions than patients without dental implants. However, the difference in the prevalence of allergy-positive reactions between groups with and without dental implants was not significant (chi-square test, $p=0.568$). Table 4 displays the prevalence of allergy-positive reactions for all metal allergens. “High-risk” metals such as mercury, palladium, chromium and nickel exhibited a higher prevalence of allergy-positive reactions than other metals. Patients who had dental implants had a significantly higher prevalence of reactions to metal allergens that contained tetrachloride titanium ($p=0.01$), but not to other metal allergens. A significant difference between these two groups was not observed for other metal allergens (Table 4).

Ninety-three (4 males, 89 females) among total 270 patients (34.4 %) had a history of contact dermatitis for jewelry such as pierced earrings, necklaces or watches. Eighty-seven patients of these 93 patients (93.5 %) exhibited an allergy-positive reaction to at least one type of metal allergen. This prevalence of positive reactions was higher than that for patients who did not have a history of contact dermatitis for jewelry (72.9 %, chi-square test, $p < 0.001$). The prevalence of positive reactions for patients with a history of contact dermatitis for jewelry (NiSO_4 : 61.3 %, $p < 0.001$; PdCl_2 : 50.5 %, $p < 0.001$; $\text{K}_2\text{Cr}_2\text{O}_7$: 40.9 %, $p = 0.045$; CoCl_2 : 33.3 %, $p = 0.003$; chi-square test for all) was higher than that for patients with no history of contact dermatitis for jewelry (Table 5). Four of ninety-three patients showed a positive reaction to a titanium allergen. Only one of the 93 participants that exhibited contact dermatitis had also received a titanium dental implant. This patient showed a positive reaction for some of metallic allergens except titanium, and presented with allergic symptoms after implantation.

Fig. 1 shows the clinical characteristics of patch tests and the number of patients who had dental implants was 16. Eleven patients among these 16 patients (68.8 %) exhibited allergy-positive reactions to at least one type of metal allergen. Only 4 patients exhibited positive reactions to titanium. Five of 16 patients had a negative reaction to all allergens. This prevalence (31.3 %) was higher than the prevalence of negative reactions in all participants (19.6 %). The total number of allergy-positive reactions for titanium allergens among 270 patients was 17 (6.3 %). All of

these patients also exhibited a positive reaction to other types of metal allergens. In other words, no patient showed a positive reaction only for titanium allergens.

3.2. Allergic symptoms in patients who had dental implants

Table 6 details the allergic symptoms experienced in patients who had dental implants. Group A (four patients) exhibited an allergy-positive reaction with a titanium allergen. Three out of the four patients showed severe allergic symptoms, and they wished have the intraoral metallic materials removed. One of these patients had all metallic restorations and the dental implant including the intra-osseous titanium implant body removed; the extent of eczema reduced completely. Two out of the remaining three patients had the metal restorations except for the dental implant and superstructure removed. Allergic symptoms of those two patients ceased after removal of the metallic material. One out of the four patients did not wish to have their intra-oral metal materials removed. Since this patient did not have severe allergic symptoms, only symptomatic therapy was conducted.

Group B (seven patients) exhibited an allergy-positive reaction to a metal allergen other than a titanium allergen. Four out of seven patients ceased having allergic symptoms upon removal of intra-oral restorations containing allergy-positive metallic materials. The remaining three out of seven patients did not wish to have the prosthesis which contained a positive metallic element removed, but wished to be followed up. However, allergic symptoms in these 3 follow-up patients did not resolve.

Group C (five patients) did not exhibit an allergy-positive reaction to any metal allergen in the patch test. However, one out of these five patients demonstrated re-test reaction during the patch test, and she did not want to retest. Her allergic symptoms ceased upon removal of metal restorations containing re-test metallic materials. The complaint from three out of five patients was an “itching sensation” and the diagnosis of an allergic symptom was difficult. Allergic symptoms in three of these patients disappeared during follow-up. One out of these five patients demonstrated lichen planus and was followed up; allergic symptoms in this patient did not resolve.

4. Discussion

In the 1980s, dental implants became one of the major choices for the treatment of missing teeth. Titanium was used as a material for dental implants at a very early stage in the development of dental implants [30,31]. The high biocompatibility of this metal suggested that titanium was an allergy-free material, and several reports supported the safety of titanium [32–34]. However, Matono et al. and Koike et al. reported that titanium can be erosive if it coexists with other types of metal, or if it is exposed to fluorine ions in acidic environments [35–37]. Various types of metal materials have been used for dental treatment, and many dentifrices contain fluoride, so the activity of titanium ions in the oral cavity could be high.

Today, titanium is used not only for medical applications such as plastic surgery and/or dental implants, but also for paints, white pigments, and various types of everyday goods. This rapid expansion of titanium-containing products has increased percutaneous and per-mucosal exposure for the population. The patch test allergen for titanium is not standardized but Nakajima described allergen composed of pure titanium powder and Vaseline that was not preferable [25]. He suggested that TiCl_4 (0.1 %) is preferable as a patch test allergen for titanium. Hence, we used allergens of TiO_2 (30 %, 10 %) and TiCl_4 (0.1 %, 0.05 %) in the present study.

Table 4

Patch-test reagents and the prevalence of allergy-positive reactions for metal reagents. Metal reagents (concentration and vehicle) used in patch testing for all patients. This list also indicates the percentages of allergy-positive patients with and without dental implants for each reagent. Only TiCl₄ exhibited a significantly higher prevalence of allergy-positive reactions for patients with dental implants than that of patients without dental implants

No	Allergen	%	Vehicle	Positive-allergy reaction of all patients	Positive-allergy reaction of patients without implants (%)	Positive-allergy reaction of patients with implants (%)	p (without vs. with implants)
1 ^a	HgCl ₂	0.1	aq	34.6	34.4	37.5	0.497
2	PdCl ₂	1	aq	34.2	34.4	31.25	0.516
3	K ₂ Cr ₂ O ₇	0.5	aq	33.1	32.8	37.5	0.444
4	NiSO ₄	5	aq	31.6	32.0	25	0.390
5 ^a	NiSO ₄	2	aq	26.0	26.9	12.5	0.165
6	CoCl ₂	2	aq	23.0	22.9	25	0.526
7	SnCl ₄	1	aq	21.2	20.9	25	0.451
8	IrCl ₄	1	aq	20.4	20.2	25	0.420
8	H ₂ PtCl ₆	0.5	aq	18.2	18.2	18.75	0.584
10 ^a	MoCl ₅	1	aq	15.6	15.0	25	0.229
11	HgCl ₂	0.05	aq	10.0	9.9	12.5	0.493
12	ZnCl ₂	2	pet	9.7	9.5	12.5	0.472
13	HAuCl ₄	0.2	aq	8.6	8.3	12.5	0.406
14 ^a	TiCl₄	0.1	aq	5.9	4.7	25	0.01
15	CuSO ₄	1	aq	4.5	4.3	6.25	0.529
16 ^a	CdSO ₄	1	aq	4.1	4.0	6.25	0.497
17	InCl ₃	1	aq	3.7	3.6	6.25	0.464
18	FeCl ₃	2	aq	3.3	3.2	6.25	0.429
19	CrSO ₄	2	aq	1.5	1.6	0	0.781
20 ^a	TiCl ₄	0.05	aq	1.5	1.2	6.25	0.218
21	Al ₂ O ₃	2	aq	0.7	0.8	0	0.884
22 ^a	SbCl ₃	1	pet	0.4	0.4	0	0.941
23	MnCl ₂	2	pet	0.4	0.4	0	0.941
24 ^a	TiO ₂	30	pet	0.4	0.4	0	0.941
25	AgBr	2	pet	0.0	0	0	–
26 ^a	TiO ₂	10	pet	0.0	0	0	–
27 ^a	BaCl ₂	0.5	aq	0.0	0	0	–
28 ^a	BaCl ₂	0.1	aq	0.0	0	0	–

No asterisk: patch-test reagent

^a Custom-made reagent**Table 5**

Prevalence of allergy-positive reactions for patients with or without a history of contact dermatitis to accessories

No	Allergen	%	Vehicle	Positive-allergy reaction for all patients (%)	Positive-allergy reaction rate for patients with a history of contact dermatitis to accessories (%)	Positive-allergy reaction for patients without a history of contact dermatitis to accessories (%)	p (without vs. with a history of contact dermatitis to accessories)
1 ^a	HgCl ₂	0.1	aq	34.6	40.9	31.1	0.108
2	PdCl₂	1	aq	34.2	50.5	24.9	0.000
3	K₂Cr₂O₇	0.5	aq	33.1	40.9	28.8	0.045
4	NiSO₄	5	aq	31.6	61.3	15.8	0.000
5 ^a	NiSO₄	2	aq	26.0	51.6	12.4	0.000
6	CoCl₂	2	aq	23.0	33.3	17.5	0.003
7	SnCl ₄	1	aq	21.2	22.6	20.3	0.668
8	IrCl ₄	1	aq	20.4	20.4	20.3	0.986
9	H ₂ PtCl ₆	0.5	aq	18.2	18.3	18.1	0.968
10 ^a	MoCl ₅	1	aq	15.6	14.0	16.4	0.604
11	HgCl₂	0.05	aq	10.0	17.2	6.2	0.004
12	ZnCl ₂	2	pet	9.7	10.8	9.0	0.650
13	HAuCl₄	0.2	aq	8.6	17.2	4.0	0.000
14 ^a	TiCl ₄	0.1	aq	5.9	4.3	6.8	0.412
15	CuSO ₄	1	aq	4.5	3.2	5.1	0.481
16 ^a	CdSO ₄	1	aq	4.1	2.1	5.1	0.246
17	InCl ₃	1	aq	3.7	4.3	3.4	0.706
18	FeCl ₃	2	aq	3.3	4.3	2.8	0.521
19	CrSO ₄	2	aq	1.5	1.0	1.7	0.689
20 ^a	TiCl ₄	0.05	aq	1.5	0	2.3	0.144
21	Al ₂ O ₃	2	aq	0.7	2.2	0	0.050
22 ^a	SbCl ₃	1	pet	0.4	1.1	0	0.167
23	MnCl ₂	2	pet	0.4	1.1	0	0.167
24 ^a	TiO ₂	30	pet	0.4	0	0.6	0.468
25	AgBr	2	pet	0.0	0	0	–
26 ^a	TiO ₂	10	pet	0.0	0	0	–
27 ^a	BaCl ₂	0.5	aq	0.0	0	0	–
28 ^a	BaCl ₂	0.1	aq	0.0	0	0	–

No asterisk: patch-test reagent

^a Custom-made reagent

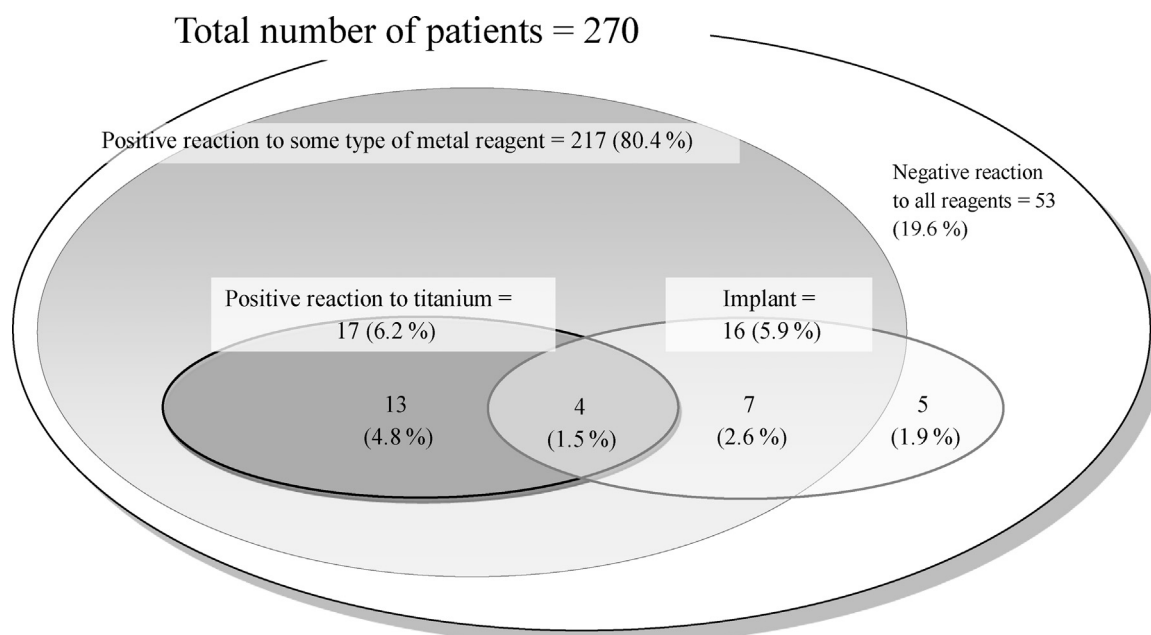


Fig. 1. Clinical characteristics of patch tests. The number of patients who had dental implants was 16. Only four patients exhibited positive reactions to titanium. Five of these sixteen patients were negative to all allergens.

We found that 17 patients (6.3%) among 270 patients exhibited an allergy-positive reaction against titanium allergens. Thirteen of these 17 patients did not have dental implants and/or orthopedic surgery with titanium products, so sensitization to titanium seemed to be due to environmental factors. The patients who had past history of contact dermatitis with jewelry exhibit higher allergy positive ratio for nickel, palladium, chromium and cobalt reagents (Table 5). So it could be suspected that the exposure for those metallic material in jewelry relevant to allergic symptoms. On the other hand titanium reagent did not exhibit such relevance with jewelry. These results suggest the potential of jewelry to induce DMA. The European Union has introduced a legal regulation on the use of nickel material for ornaments such as earrings. Our data suggest that a similar type of regulation should be considered in Japan.

The prevalence of allergy-positive reactions against titanium allergens was lower than for “risky” materials such as chromium, mercury, palladium and nickel, and no patient exhibited an allergy-positive reaction only for a titanium allergen in this study. Cross-reactions from different types of metal material may cause titanium allergy. However, the patient group that had dental implants exhibited a higher prevalence of allergy-positive reactions against titanium allergens than the group that did not have dental implants. This finding suggests that dental implants may increase the risk of titanium sensitization.

The symptoms of DMA can be seen in the oral mucosa as well as palmar, plantar and skin surfaces. Hence, finding the cause of allergy by observation of symptoms only is difficult. Another feature of DMA is that patients cannot stop exposure to the allergen by themselves unless the material in the denture is the cause of allergy. The allergenic material remains in the mouth, so the symptoms of DMA cannot be ablated by medication. Hence, if inflammation of skin (e.g., erythema, eczema, blisters) occurs and anti-allergic agents and other dermatologic treatments are ineffective, DMA should be suspected. Skin eruptions with rings, earrings and other piercings, metallic necklaces, wristwatches, or spectacle frames can be additional signs of DMA. Problems on the skin and intra-oral mucosa after dental treatment with metal materials also suggest DMA. However, even in such cases, immediate removal of metallic restorations should be avoided.

Careful follow-up and identification of the metal material causing the allergic symptoms by patch testing is indispensable. High-risk restorations that contain chemically unstable metallic material should be removed, and step-by-step follow-up after removal of each material should be undertaken.

In our study, one of four titanium-allergy patients was relieved of allergic symptoms after removal of all titanium materials (including dental implants), whereas another patient recovered without removal of dental implants. Individual titanium sensitivity may explain this difference in treatment response. The second patient had all metallic restorations removed other than dental implants, so the loss of galvanic action between the titanium implant and other oral restorations might have reduced titanium elution. We cannot predict the details of each patient's reaction, so removal of intra-oral metallic material using a step-by-step procedure should be undertaken.

Our study showed a higher prevalence of allergy-positive reactions than reports using identical [38] or other patch-test methods [39–41]. The background of our patients may have been different from those of previous studies that evaluated the general patient population because 96% of our patients were referred from dental departments or dermatology departments with a diagnosis (or suspected diagnosis) of metal allergy. We think that the response to DMA by local dentists and dermatologists increased the number of referrals and prevalence of allergy-positive results in those patients. Hence, we believe that adequate knowledge of DMA will be helpful for patients suffering from incurable eruptions, itching and/or pain in the oral mucosa.

The number of patients confirmed to have titanium allergy with implant prostheses was very small. Most of the patients in our clinic were referrals and a supposedly high-risk group for allergy. Hence, it could be speculated that the prevalence of titanium allergy-positive cases in the normal population might be far less than that stated in the present study. New studies involving multi-institutional etiological investigations are required to clarify the prevalence of titanium allergy. Moreover, several examinations have been reported for sensitivity and/or allergy test of titanium material [42,43]. In those examination, inflammation markers such as IL-17 and IL-22 are used as the immunological assay. Although

Table 6

Details of allergic symptoms experienced by patients who had dental implants

Group	Patient number	Sex	Symptom	Region	Positive elements of patch test															Episode of care	Progress
Group A Positive for titanium reagent	1	M	Rash	Whole body	Cu	Pd	Cr	Co	Hg	Sn	Cd	Au	Pt	Fe	In	Ir	Mo	Zn	Ti	All removed	Improved
	2	M	Pustulosis palmaris et plantaris	Hands and feet	Hg	Sn	Pt	Ti												All removed other than implants	Improved
	3	M	Lichen planus	Oral cavity	Pd	Cr	Hg	Sn	Au	Pt	Ir	Mo	Ti							All removed other than implants	Improved
	4	F	Discomfort	Oral cavity	Cr	Zn	Ti													Not removed × follow-up	Improved slightly
Group B Positive for reagents other than titanium	8	M	Urticaria	Whole body	Pd	Sn	Ir													Positive metal removed	Improved
	9	F	Soreness	Oral cavity	Ni	Hg														Positive metal removed	Improved
	10	M	Itching	Whole body	Ni															Not removed × follow-up	Improved
	6	F	Discomfort	Oral cavity	Pd	Cr	Ni	Co	Ir											During removal	Improved slightly
	5	F	Lichen planus	Oral cavity	Pd	Cr	Co	Hg												Not removed × follow-up	No change
	7	M	Stomatitis	Oral cavity	Cr	Ni	Co	Mo												Not removed × follow-up	No change
	11	F	Discomfort	Oral cavity	Hg															Not removed × follow-up	No change
Group C Negative for all reagents	13	F	Crazing of a nail	Hands and feet																Pseudo-positive metal removed	Improved
	14	M	Itching	Whole body																Not removed × follow-up	Improved
	15	F	Itching	Whole body																Not removed × follow-up	Improved
	16	F	Itching	Whole body																Not removed × follow-up	Improved
	12	F	Lichen planus	Oral cavity																Not removed × follow-up	No change

Group A exhibited an allergy-positive reaction with a titanium reagent.

Group B exhibited an allergy-positive reaction for a metal reagent other than a titanium reagent.

Group C did not exhibit an allergy-positive reaction for any metal reagent in the patch test.

All removed; removed all metallic material that including the intra-osseous titanium implant body.

Removed except for implants; removed metallic material except for dental implant and superstructure.

Removed positive metal; removed metallic material that exhibited allergy positive reactions.

During removal; halfway of removing metallic materials.

Removed pseudo-positive metal; removed metallic materials that exhibited pseudo-positive reaction during patch test (see Table 2).

Not removed; patients did not want to remove allergy positive metal materials.

those examinations exhibited high reliability, clinical use of those techniques are not widely spread yet. Since those examination needs blood samples, non-invasive method that enable higher reliability of titanium allergy will be required.

However, the results of the present study showed that titanium allergy exists, even if the number was small. Hence, dentists and clinicians who may use titanium for biomaterials should be aware that there is no completely biocompatible metallic material.

5. Conclusion

The prevalence of allergy-positive reactions to titanium allergens was lower than for other metal allergens. However, the results of the present study showed that titanium allergy exists. The findings of this study deny the null hypothesis that

there is no titanium allergy in patients caused by dental implants. We suggest an examination of pre-implant patients who have a history of hypersensitivity reactions to metals.

Acknowledgments

The authors express their gratitude to Professor Emeritus Eiichi Bando. Moreover, many thanks go to all our patients who took part in this study. This study was supported in part by a Grant-in-Aid for Scientific Research of Japan (research project number: 25463003).

References

- [1] Fleischmann P. Zur Frage der Gefährlichkeit Kleinsten Quecksilbermengen. Dtsch Med Wochenschr 1928;54:304.

- [2] Blumenthal F, Jaffe K. Amalgamplomben als Ursache von Quecksilberdermatitis. *Dtsch Med Wochen sch* 1929;55:1720.
- [3] Magnusson B, Bergman M, Bergman B, Söremark R. Nickel allergy and nickel-containing dental alloys. *Scand J Dent Res* 1982;90:163–7.
- [4] Hubler WR Jr, Hubler WR Sr. Dermatitis from a chromium dental plate. *Contact Dermatitis* 1983;9:377–83.
- [5] Lundström IM. Allergy and corrosion of dental materials in patients with oral lichen planus. *Int J Oral Surg* 1984;13:16–24.
- [6] Gawkrödger DJ. Investigation of reactions to dental materials. *Br J Dermatol* 2005;153:479–85.
- [7] Yanagi T, Shimizu T, Abe R, Shimizu H. Zinc dental fillings and palmoplantar pustulosis. *Lancet* 2005;366:1050.
- [8] Hosoki M, Bando E, Asaoka K, Takeuchi H, Nishigawa K. Assessment of allergic hypersensitivity to dental materials. *Biomed Mater Eng* 2009;19:53–61.
- [9] Hosoki M, Nishigawa K. Dental metal allergy. In: Ro YS, editor. *Contact dermatitis*. Croatia: InTech; 2011. p. 119–38.
- [10] Hensten-Petersen A. Casting alloys: side-effects. *Adv Dent Res* 1992;6:38–43.
- [11] Garau V, Masala MG, Cortis MC, Pittau R. Contact stomatitis due to palladium in dental alloys: a clinical report. *J Prosthet Dent* 2005;93:318–20.
- [12] Bass JK, Fine H, Cisneros GJ. Nickel hypersensitivity in the orthodontic patient. *Am J Orthod Dentofac Orthop* 1993;103:280–5.
- [13] Jia W, Beatty MW, Reinhardt RA, Petro TM, Cohen DM, Maze CR, et al. Nickel release from orthodontic arch wires and cellular immune response to various nickel concentrations. *J Biomed Mater Res* 1999;48:488–95.
- [14] Kim H, Johnson JW. Corrosion of stainless steel, nickel-titanium, coated nickel-titanium, and titanium orthodontic wires. *Angle Orthod* 1999;69:39–44.
- [15] Suhonen R, Kanerva L. Allergic contact dermatitis caused by palladium on titanium spectacle frames. *Contact Dermatitis* 2001;44:257–8.
- [16] Bircher AJ, Stern WB. Allergic contact dermatitis from “titanium” spectacle frames. *Contact Dermatitis* 2001;45:244–5.
- [17] Walsh G, Mitchell JW. Free surface nickel in CE-marked and non-CE-marked spectacle frames. *Ophthalmic Physiol Opt* 2002;22:166–71.
- [18] Peters MS, Schroeter AL, van Hale HM, Broadbent JC. Pacemaker contact sensitivity. *Contact Dermatitis* 1984;11:214–8.
- [19] Lalor PA, Revell PA, Gray AB, Wright S, Railton GT, Freeman MA. Sensitivity to titanium. A cause of implant failure? *J Bone Joint Surg Br* 1991;73:25–8.
- [20] Holgers KM, Thomsen P, Tjellström A. Persistent irritation of the soft tissue around an osseointegrated titanium implant. Case report. *Scand J Plast Reconstr Surg Hand Surg* 1994;28:225–30.
- [21] Abdallah HI, Balsara RK, O’Riordan AC. Pacemaker contact sensitivity: clinical recognition and management. *Ann Thorac Surg* 1994;57:1017–8.
- [22] Thomas P, Bandl WD, Maier S, Summer B, Przybilla B. Hypersensitivity to titanium osteosynthesis with impaired fracture healing, eczema, and T-cell hyperresponsiveness in vitro: case report and review of the literature. *Contact Dermatitis* 2006;55:199–202.
- [23] Egusa H, Ko N, Shimazu T, Yatani H. Suspected association of an allergic reaction with titanium dental implants: a clinical report. *J Prosthet Dent* 2008;100:344–7.
- [24] Siddiqi A, Payne AG, De Silva RK, Duncan WJ. Titanium allergy: could it affect dental implant integration? *Clin Oral Implants Res* 2011;22:673–80.
- [25] Nakajima K. Study on patch test reagent for titanium. *Kokubyo Gakkai Zasshi* 2007;74:92–8.
- [26] Lachapelle J-M, Maibach HI. Patch testing and prick testing: a practical guide official publication of the ICDRG. 2nd ed. Berlin: Springer; 2009.
- [27] Fage SW, Muris J, Jakobsen SS, Thyssen JP. Titanium: a review on exposure, release, penetration, allergy, epidemiology, and clinical reactivity. *Contact Dermatitis* 2016;74:323–45.
- [28] Sigrid F. *Manual of contact dermatitis*. 2nd ed. Copenhagen: Munksgaard; 1981.
- [29] Inoue M. The status quo of metal allergy and measures against it in dentistry. *J Jpn Prosthodont Soc* 1993;37:1127–38.
- [30] Breine U, Bränemark PI. Reconstruction of alveolar jaw bone. An experimental and clinical study of immediate and preformed autologous bone grafts in combination with osseointegrated implants. *Scand J Plast Reconstr Surg* 1980;14:23–48.
- [31] Bränemark PI, Adell R, Albrektsson T, Lekholm U, Lundkvist S, Rockler B. Osseointegrated titanium fixtures in the treatment of edentulousness. *Biomaterials* 1983;4:25–8.
- [32] Wataha JC, Hanks CT, Sun Z. Effect of cell line on in vitro metal ion cytotoxicity. *Dent Mater* 1994;10:156–61.
- [33] Steinemann SG. Titanium-the material of choice? *Periodontol* 2000 1998;17:7–21.
- [34] Larese Filon F, Mauro M, Adami G, Bovenzi M, Crosera M. Nanoparticles skin absorption: new aspects for a safety profile evaluation. *Regul Toxicol Pharmacol* 2015;72:310–22.
- [35] Koike M, Fujii H. In vitro assessment of corrosive properties of titanium as a biomaterial. *J Oral Rehabil* 2001;28:540–8.
- [36] Matono Y, Nakagawa M, Matsuya S, Ishikawa K, Terada Y. Corrosion behavior of pure titanium and titanium alloys in various concentrations of acidulated phosphate fluoride (APF) solutions. *Dent Mater J* 2006;25:104–12.
- [37] Fragou S, Eliades T. Effect of topical fluoride application on titanium alloys: a review of effects and clinical implications. *Pediatr Dent* 2010;32:99–105.
- [38] Hamano H, Uoshima K, Miao WP, Masuda T, Matsumura M, Hani H, et al. Investigation of metal allergy to constituent elements of intraoral restoration materials. *Kokubyo Gakkai Zasshi* 1998;65:93–9.
- [39] Smith-Sivertsen T, Dotterud LK, Lund E. Nickel allergy and its relationship with local nickel pollution, ear piercing, and atopic dermatitis: a population-based study from Norway. *J Am Acad Dermatol* 1999;40:726–35.
- [40] Akyol A, Boyvat A, Peksari Y, Gürgey E. Contact sensitivity to standard series allergens in 1038 patients with contact dermatitis in Turkey. *Contact Dermatitis* 2005;52:333–7.
- [41] Khamaysi Z, Bergman R, Weltfreund S. Positive patch test reactions to allergens of the dental series and the relation to the clinical presentations. *Contact Dermatitis* 2006;55:216–8.
- [42] Oboki K, Ohno T, Saito H, Nakae S. Th17 and allergy. *Allergol Int* 2008;57:121–34.
- [43] Ricciardi L, Minciullo PL, Saitta S, Trombetta D, Saija A, Gangemi S. Increased serum levels of IL-22 in patient with nickel contact dermatitis. *Contact Dermatitis* 2009;60:57–8.